

Sequential Cranial Angiography of Young Red Deer Stags

J. M. Suttie, P. F. Fennessy, C. G. Mackintosh, I. D. Corson, R. Christie* and S. W. Heap†

Invermay Agricultural Research Centre, Ministry of Agriculture and Fisheries, Mosgiel, New Zealand
Department of Surgery and †Department of Radiology, University of Otago Medical School, Dunedin, New Zealand

Abstract

The blood supply to the pedicle and first antler of the red deer stag (*Cervus elaphus*) during their development has been examined by injecting a radio-opaque marker into the carotid and taking radiographs at intervals. The lateral branches of the superficial temporal artery (STA) supply the pedicle and antler. The STA does not pass through the carotid rete.

Keywords: angiography, pedicle, antler, *Cervus elaphus*

Introduction

Previous studies on the arterial supply to the head and antlers of deer have depended on dissection of postmortem material after injection of dye or radio-opaque materials (Wislocki 1942; Waldo *et al* 1949; Adams 1979). The cranial supply resembles closely that of cattle and sheep (Sisson 1914) with the antler supplied by branches of the superficial temporal artery.

The aim of the present study was to follow the development of the arterial supply to the pedicle and first antler during their development.

Materials and Methods

Surgery

Three 3-month-old red deer stags (*Cervus elaphus*) were prepared with a prosthesis to enable simple repeated cannulation of the carotid artery. The procedure was: under Fluothane anaesthesia, with full aseptic precautions, a 10 cm length of the right carotid artery was exposed and carefully dissected free of the vagus nerve. A 7 cm length of polythene tubing (17 mm outer diameter, 13 mm internal diameter) cut half way along its length and with a 4.5 × 1 cm hole midway, was placed round the artery and sutured into place using 3-0 metric silk. Muscle layers were sutured behind the prosthesis and the skin was sutured above the prosthesis.

Angiography

At monthly intervals selected red deer were placed under Fluothane (I.C.I., U.K.) anaesthesia and the carotid palpated and cannulated through the skin

via the hole in the prosthesis using a G19 butterfly cannula (Venofix Braun Melsungen AG, West Germany). Saline containing 25 000 IU litre⁻¹ heparin was infused at greater than arterial pressure to maintain patency of the cannula during the procedure. A volume of 15–20 ml 76% radio-opaque contrast medium (Urograffin, Schering AG, Berlin) was injected manually via the cannula as rapidly as possible (about 5–10 seconds).

Simultaneously a Siemens X-ray machine, with a rotating anode, using a 1 mm focal spot, was used to take radiographs on XRP1 (Agfa) blue sensitive film. An Elema Schonander rapid film changer was used to permit up to 4 radiographs to be taken per second for 15 seconds. The exposure varied between 48–70 pkV and 20–40 mAS depending on whether the antler or head was being X-rayed and on the size of the animal; the focus-film distance was 1.2 m. On some occasions, Min-R film (Kodak) was also used.

Results and Discussion

The pattern of blood supply to head, pedicle, and antler revealed by the angiography is shown in Fig. 1. The lateral branches of superficial temporal artery (STA) supply the pedicle and antler. Fig. 2 illustrates the arterial supply and venous drainage from the head prior to any development of the pedicle. In Fig. 3 the arterial supply during early pedicle development is shown; in contrast to Fig. 2, the branches of STA supplying the pedicle are now readily apparent. Fig. 4 shows the arterial supply at 2 different stages of antler development; in early antler the branches of the STA are apparent (Fig. 4a) but in late antler they are extremely

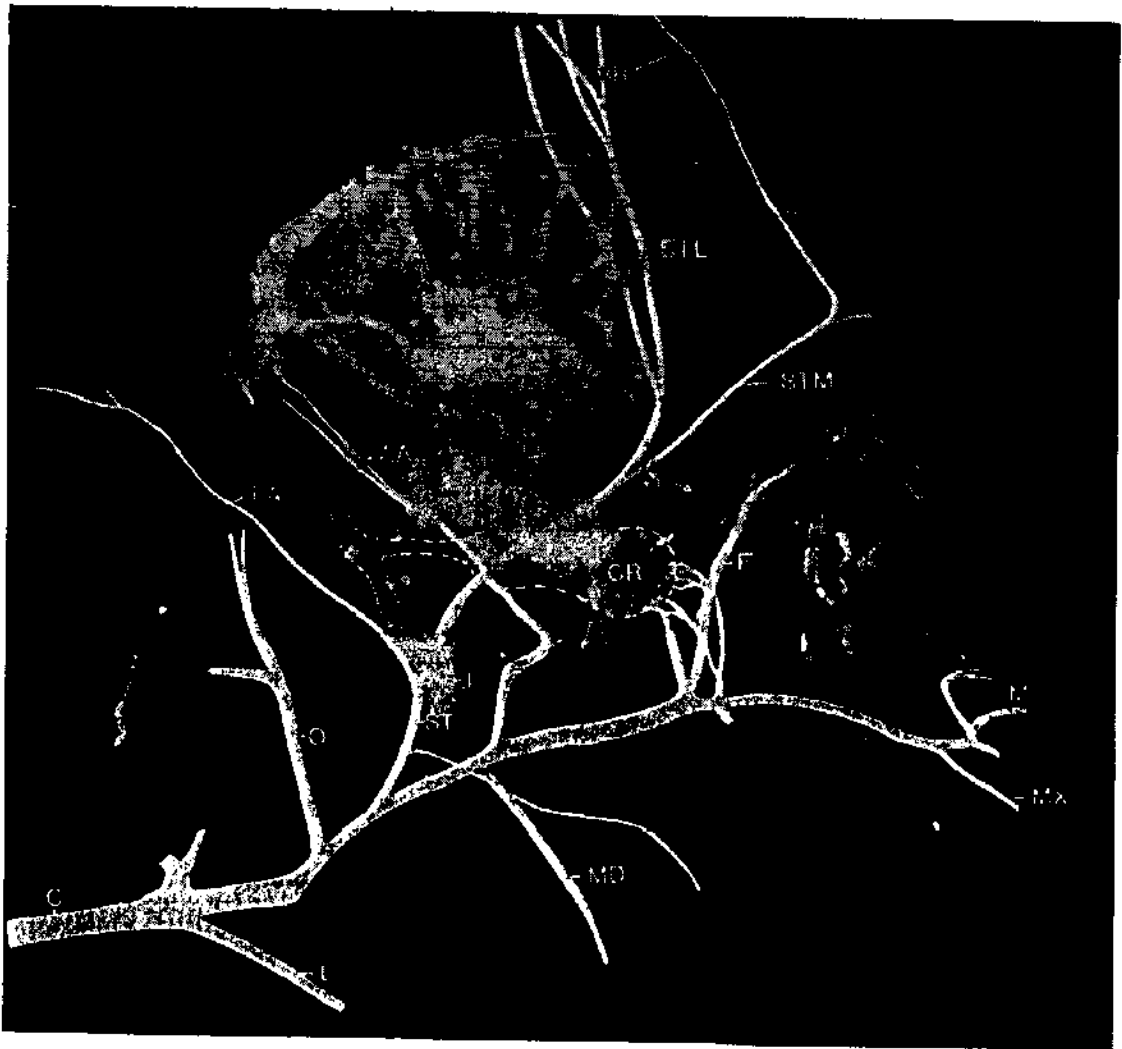


Fig. 1: Pattern of arterial supply to the head of the stag during antler development. This angiograph is of deer 118 (head) on 19 November 1982 at mid-antler development, taken 7 seconds after injection. (Key — all arteries unless specified: C, carotid; L, lingual; O, occipital; ST, superficial temporal; PA, post-auricular; STL, lateral branch of ST; STM, medial branch of ST; BR, branches to antler; AA, anterior auricular; MD, mandibular; F, frontal; M, malar; MX, external maxillary; J, jugular vein; CR, carotid rete)

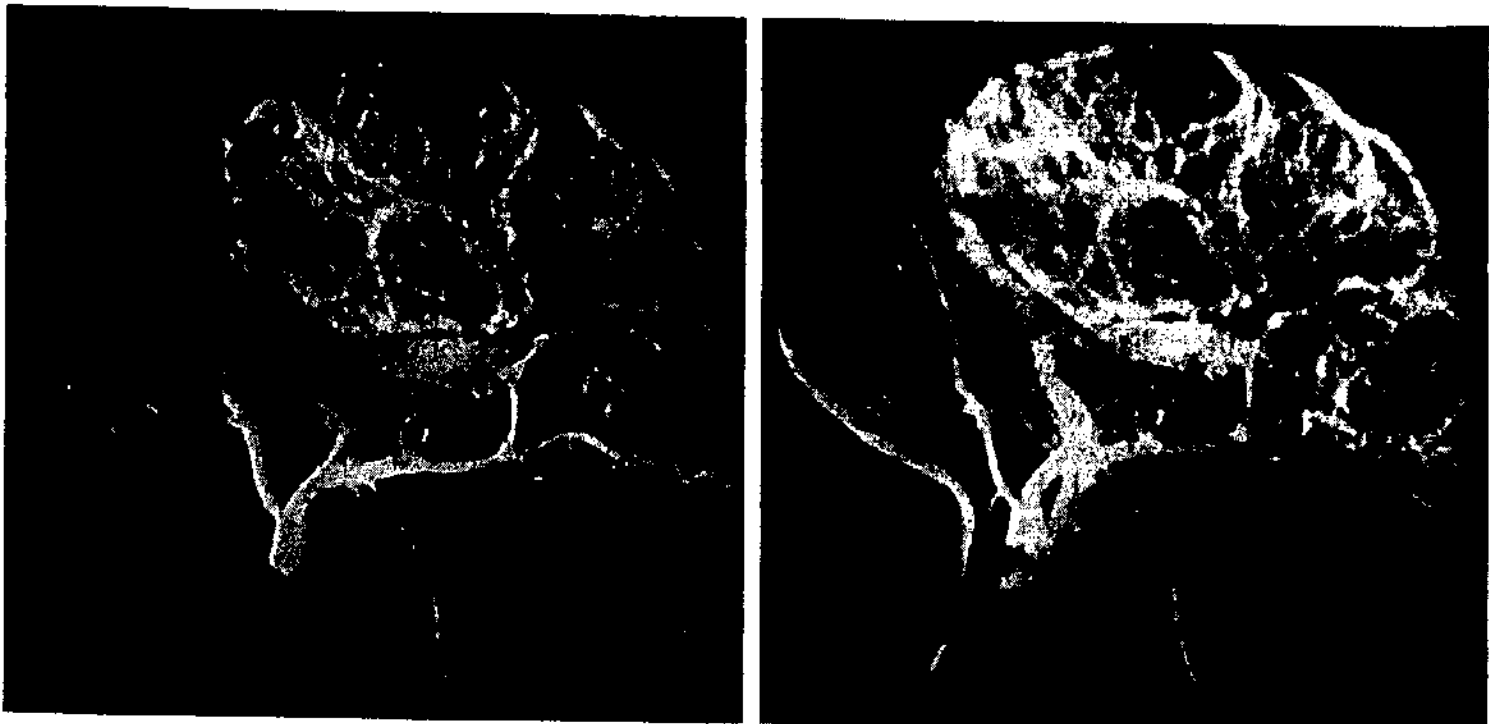


Fig. 2: Deer 152 (head) on 2 April 1982 prior to any pedicle development: (*left*) arterial supply, taken 3 seconds after injection; only a small section of the STA is readily apparent at this stage; (*right*) venous drainage, taken 6 seconds after injection; the jugular vein is very prominent.

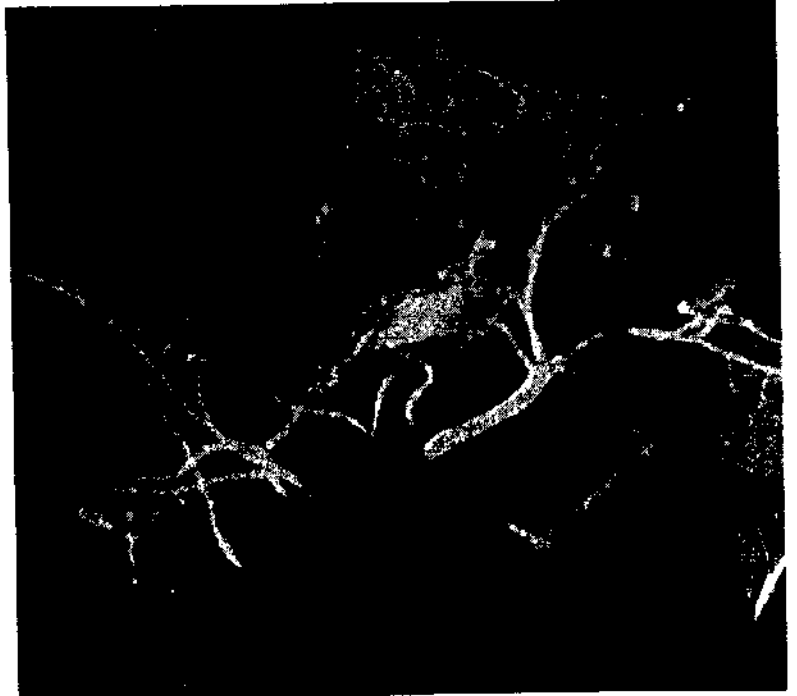
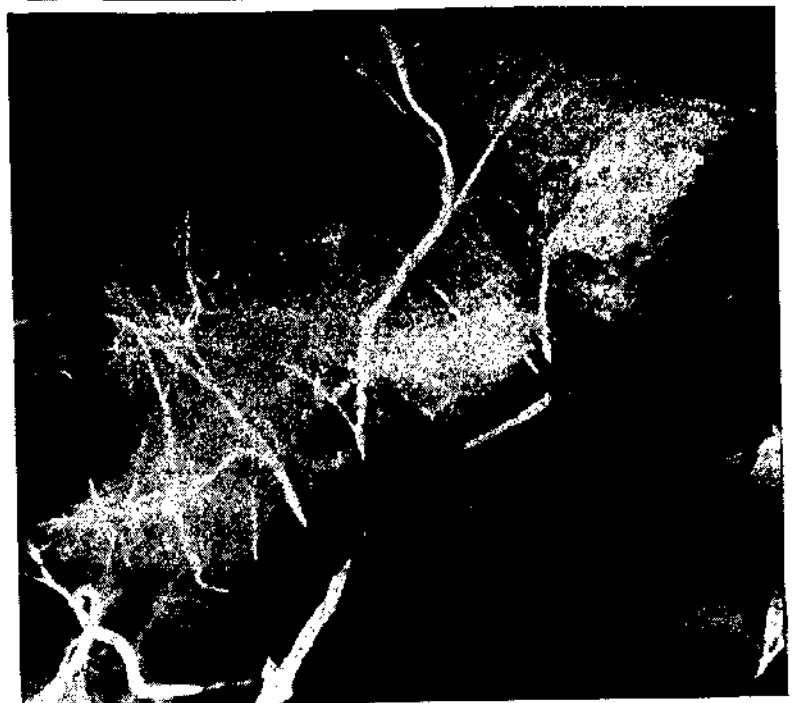


Fig. 3: Deer A (head) on 28 May 1982 when small pedicles were present; the development of the medial branch of the STA is now clearly evident.

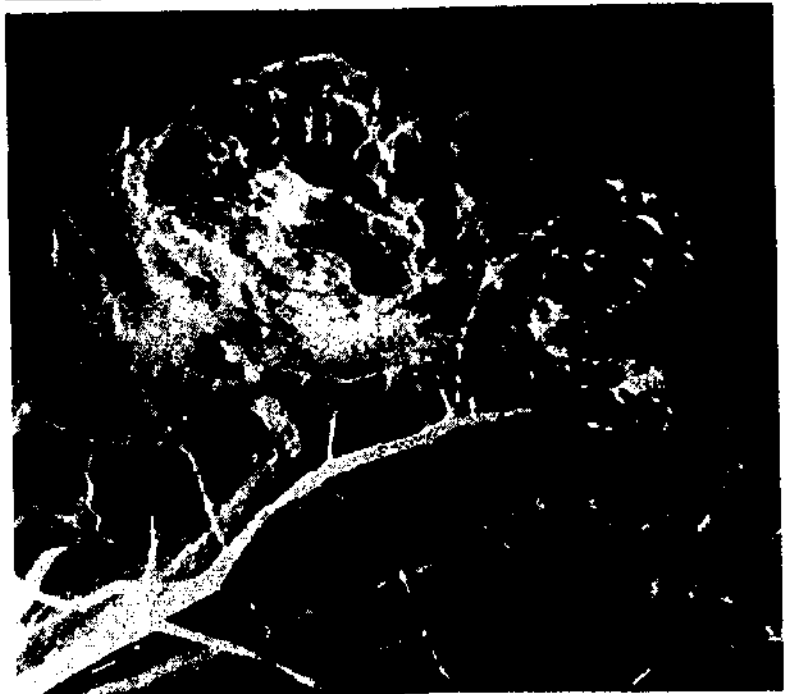

Fig. 4: Deer 118 (head): (*upper*) 12 October 1982 in early antler development, 7 seconds after injection; (*lower*) 14 January 1983 in late antler development, 7 seconds after injection. (*Note:* Fig. 1 is of the same deer taken at mid-antler development.)



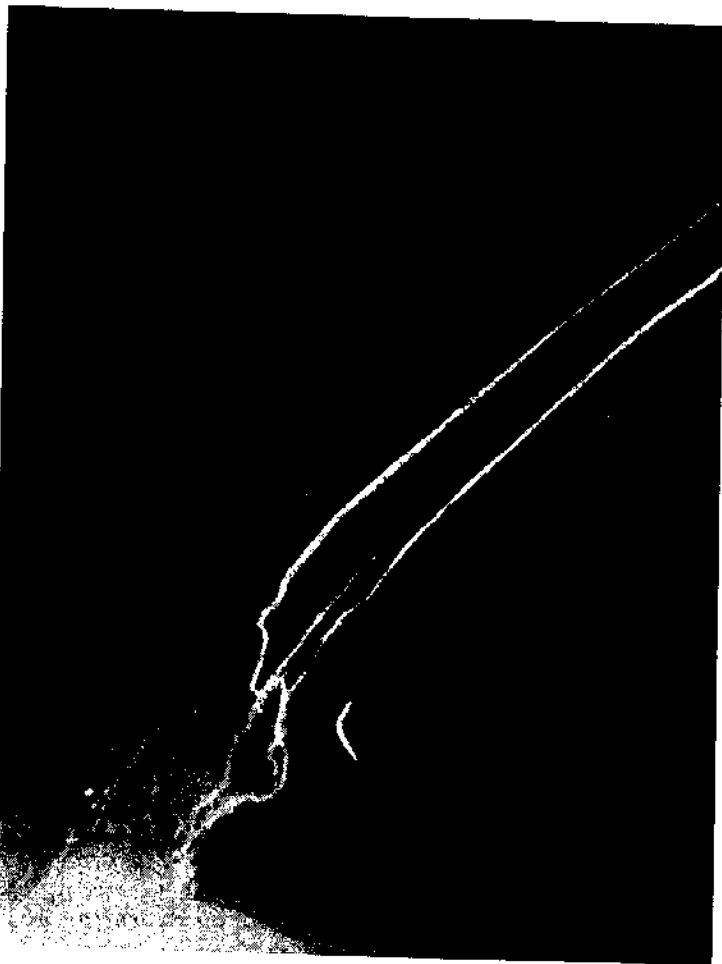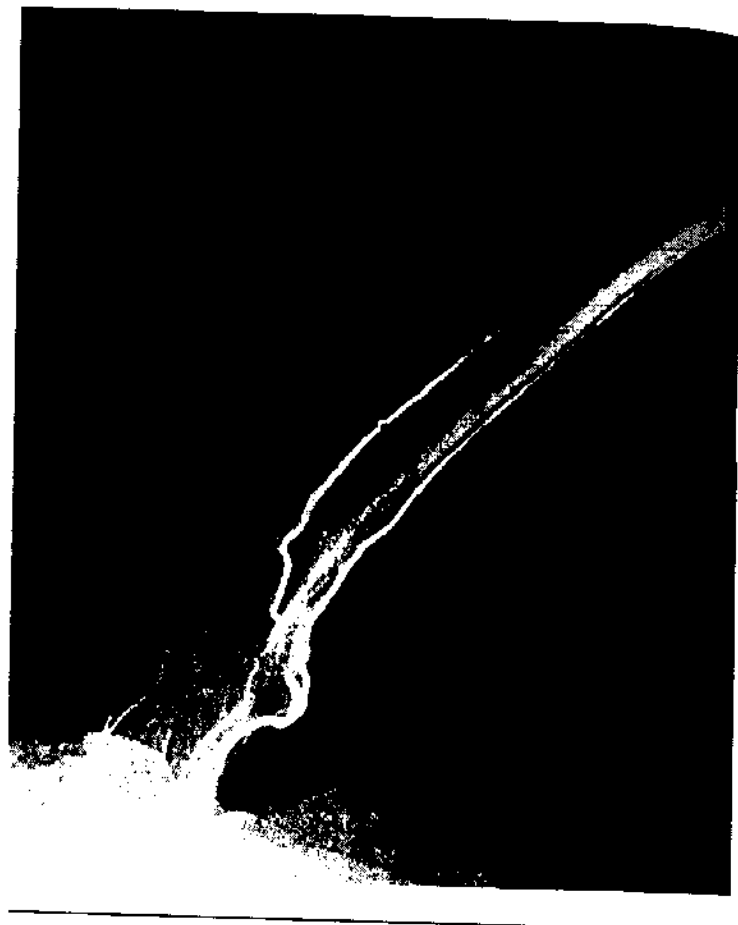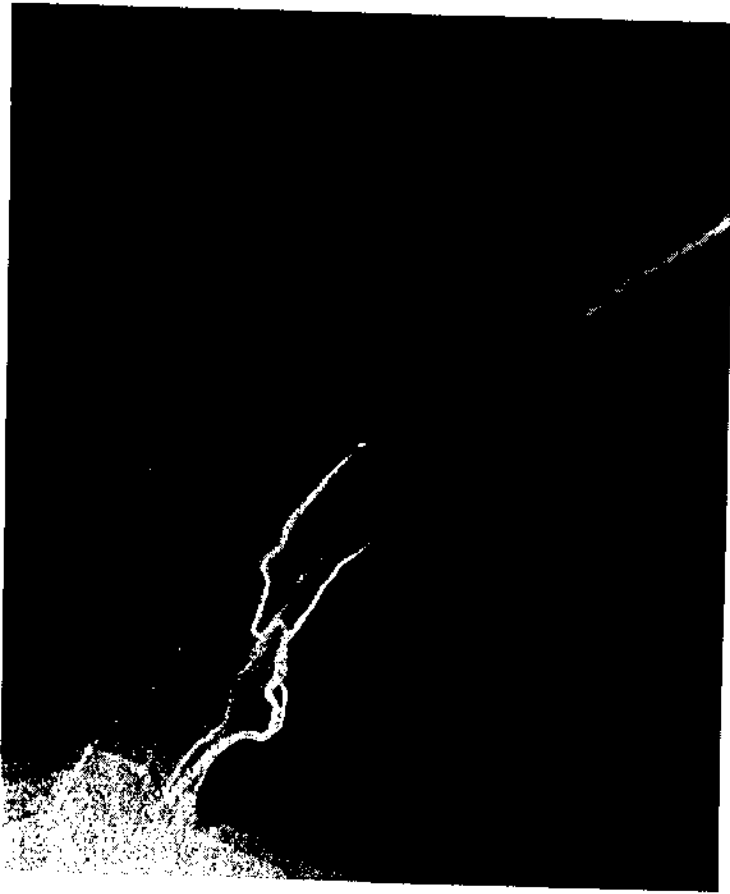


Fig. 5: Deer 118 (antler) on 19 November 1982 in mid-antler development: a sequence of radiographs taken 10 (*upper left*), 11 (*upper right*), and 12 seconds (*lower*) after injection.

prominent (Fig. 4b). Overall the angiographs indicate that the STA increases in both diameter and length from pedicle initiation through antler growth.

A single major branch of the STA divides above the coronet and 1 branch crosses the antler from the posterior to the anterior as shown in Fig. 5 and 6. A capillary bed is evident about 1 cm below the antler tip (Fig. 7); this is consistent with the theory that the arterial supply to the antler is peripheral but that much of the venous drainage is central via the cartilage and bone trabeculae.

The superficial temporal artery does not pass through the carotid rete. It is thus highly unlikely that the antler plays a role in thermo-regulation. After the antler is cleaned of velvet, no blood supply reaches the antler, although the pedicle remains well supplied (Fig. 8).

Acknowledgements

We wish to thank Prof. A Clarke, Department of Surgery, University of Otago, for permission to use facilities. The staff of the Radiology Department, particularly Cherie Esquilant, were responsible for taking the radiographs.




Fig. 6: Deer 118 (antler) on 14 January 1983 in late antler, taken 12 seconds after injection.




Fig. 7: Deer 118 (antler): (left) on 19 November 1982; (right) 14 January 1983. (Kodak, Min-R film; 46 pkV, 20mAS; taken 12 seconds (left) and 14 seconds (right) after injection. The left contralateral antler was removed flush with the temporal bone to remove X-ray shadow.)




Fig. 8: Deer 118 (antler) on 25 February 1983. 10 seconds after injection; antler growth is complete and the antler has been cleaned of velvet.

References

- Adams J I. 1979 Innervation and blood supply of the antler pedicle in the red deer. *N.Z. vet. J.* 27: 200-201.
- Sisson S 1914 *The Anatomy of Domestic Animals* (2nd ed.) W B Saunders, Philadelphia.
- Waldo C M, G B Wislocki and D W Fawcett 1949 Observations on the blood supply of growing antlers. *Amer. J. Anat.* 84: 27-61.
- Wislocki G B 1942 Studies on the growth of deer antlers I. On the structure of the antlers of the Virginia deer (*Odocoileus virginianus borealis*). *Amer. J. Anat.* 71: 371-416.